*International Journal of Research in Advent Technology, Special Issue, ICATESM 2019*
*E-ISSN: 2321-9637*
*Available online at www.ijrat.org*

# A Review on Acute Ischemic Stroke Detection and Classification

S. R. Tongase[1],S. S.Thorat[2]
(P.G. Scholar)
*Electronics System and Communication Engineering GCOEA,. Amravati*
*Email: shubhamtongase@gmail.com[1] , snehsnehu@gmail.com[2]*

**Abstract—** Stroke is ahead in reason of death in country under development like India. A stroke may cause by blockage of artery (ischemic stroke) or leaking or exploding of a blood vessel (hemorrhagic stroke). Almost 80 percent of strokes are ischemic stroke. Hence to detect the stroke in early stages will be beneficial for the patient in the rehabilitation process. Computed Tomography Scan images are widely for the diagnosis of stroke. In CT images ischemic stroke seems as dark area with the contrast, congener to its surrounding This paper depicts the different method used by various researchers of detection of stroke and its classification.

**Keywords—** Stroke Detection, CT scan, classification, MRI

## 1. INTRODUCTION

Stroke is a Cerebro Vascular Accident (CVA) which is major health problem and it is ahead in death worldwide. In developing countries stroke is in the lead in cause of disability, dementia and death. Stroke not only affect the person who may be disabled, but their family. Stroke is cause by disruption of blood supply to the brain, usually because blood vessel burst or block due to blood clot as shown in Fig. 1. This disruption of supply of oxygen and nutrients to the brain, results into the damage of brain tissue. Stroke is subdivided into two major types these are Ischemic and Hemorrhagic. The ischemic stroke is caused by abrupt occlusion of arteries supplying the brain. It accounts for 50% to 85% of all stroke worldwide. Hemorrhagic stroke are cause by subarachnoid hemorrhage- bleeding from one of the brain arteries into the brain tissue or intra-cerebral hemorrhage - arterial bleeding. This category stroke accounts for 1% to 7%.

In 2011, it is figured 6.2 million population died because of stroke worldwide[2]. Stroke could potentially tend to tremendous social burden and a substantial encroachment on health resources in the development of the National health system[1]. Computed Tomography (CT) scan and Magnetic Resonance Imaging (MRI) images is generally used for the identifying the nature and cause of stroke patient. Hemorrhage appears bright region well contrast verses its surrounding in CT scan images whereas Ischemic appears as dark region against its surrounding depend on the time passed since the stroke occurred.

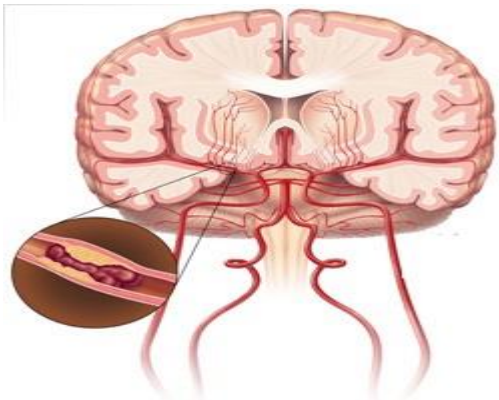

Fig. 1 An ischemic stroke occur when the arteries in the brain become block (Source: Ref [3]).

This paper presents a revise on related work done about acute ischemic stroke detection and classification. And analyze the detection and classification accuracy of the former research done.

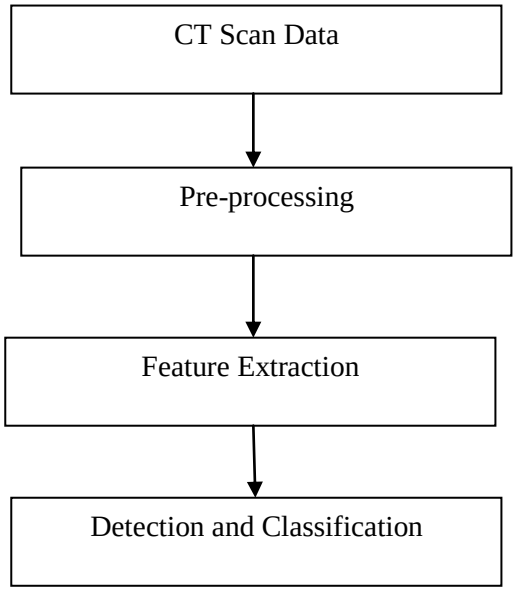


Fig. 2 Generalized Block Diagram of Methodology

## 2. LITERATURE SURVEY

Diagnosis of acute ischemic stroke in early stages is the need. CT scan images play a vital role for the analysis of the stroke and its type. Various Computer Aided Diagnosis (CAD) systems are developed with different methodology and algorithm in the previous research. These systems are helpful in the detection of early Cerebro Vascular Accident (CVA) symptoms.

P. R. Mirajkar [4] derived a method for the detection of acute ischemic stroke using CT scan images and MRI. Fusion of CT scan images and Diffusion Weighted MRI gives a composite image which gives more information than single modality. DICOM image is used in the preprocessing in which various operations such as skull stripping, noise removal and edge sharpening is performed. CT image equivalent to MRI image is selected using LPP (Locality Preserving Projection) algorithm. After image registration, image fusion is accomplished using Discrete Wavelet Transform (DWT). Fusion performance is evaluated using Root Mean Square Error (RMSE) and Peak Signal to Noise Ratio (PSNR) Segmentation of stroke region is K-Means clustering method is employed. The algorithm is tested on 18 cases and for 16 cases stroke region is identified precisely.

A. F. Z. Yahiaoui [5] proposed a method to segment the ischemic stroke form CT brain images. In preprocessing noise and skull part is removed and new region is defined. Preprocessed image is then reconstructed and decomposed using Laplacian Pyramid and simple nonlinear enhancement function. Laplacian Pyramid algorithm gives better result than DWT in the image enhancement. FCM clustering technique is used for the segmentation of stroke region form CT images. Average processing time is achieved is 10.46 s.

Dr. Menaka R [6] propose a method to detect the ischemic stroke form MRI images employing wavelet transform. MRI images of stroke patient is collected and median filter is applied to remove noise from the image. Normal and abnormal brain is classified based on right and left side of the brain which is achieve using watershed segmentation. Texture analysis is performed using Grey Level Co-occurrence Matrix (GLCM) and wavelet features extracted. Neural Network eliminate the difficulties in image processing which is design using the Neural Network Toolbox. Feature extraction technique is implemented to detect the lesion region. Neural Network is implemented on FPGA by creating Xillinx Simulink Blocks.

Jeena R S [7] analyze the MRI and CT brain images for stroke diagnosis. Preprocessing of input images is done using median filtering to remove noise. Concept of texture segmentation is exploited using Gabor Filtering. Seeded region growing is also implemented and result is compared. Ischemic stroke detection is difficult in CT images than in MRI images. For the proposed algorithm the computational time is very less.

Md Tabish raza [8] propose the comparison based method for ischemic tissue detection using CBV and MTT perfusion map. In preprocessing, DICOM file is used to perform image analysis with perfusion map CBV and MTT. Computation of threshold for the CBV and MTT map is performed by creating the histogram of both maps. The classification of brain tissue is done as normal tissue, dead tissue, dying tissue and undefined condition using CBV and MTT map.

T. L. Tan [9] proposed a method to enhance the contrast of CT brain images for the detection of acute ischemic stroke. This study exhibit method which enhances the soft tissue area and conserves the background brightness. First, the unwanted pixels in a CT brain images are clipped, then PDF and CDF are calculated. Normalization is done by dividing the new CDF by its last element. This result is used as the transform function and applied to input image. Enhancement Entropy (EMEE) and PSNR is calculated to compare the proposed method with the conventional method.

Kiran Parmar [10] analyze the CT and MRI image fusion using wavelet transform. Five wavelet families used for fusing CT and MRI images. The filter Daubechies provide the least RMSE was selected for further processing. Various fusion rules are tested, including the mean rule , maximum rule, minimum rule and random rule. Maximum rule is found to be better hence it is applied to three CT and MRI images. Maximum fusion rule achieves least MSE and higher PSNR values.

Mayank Chawla [11] proposed an algorithm for the detection and classification of stroke using brain CT images. Contrast is stretched using Windowing operation above the peak value. Noise is removed by using Weiner filtering. Rotation correction is achieve to adjust the inclined image. The detection of abnormal slices is done by plotting their histogram. Classification of the normal and acute infarct cases is achieve using Daubchies-4 wavelet decomposition up to level 5 is used.

Teena Thomas [12] proposed a method for the detection of ischemic stroke utilizing cellular automata. CT image is converted into binary image to remove skull part and median filtering is performed to remove noise. Bezier curve is used to separate two hemispheres. Feature extraction is perform using co-occurrence matrix which is statistical method used for texture analysis. Classification is done using Support Vector Machine classifier to divide normal and ischemic stroke images, achieves the accuracy of 98%.

Ming sian, Lee [13] propose the increased visual perception stroke detection system. Firstly, contrast of CT scan is enhanced in preprocessing. Anisotropic filter eliminate the noise and brain region is extracted using mathematical morphology. Median filter is used for noise removal and keep the edge information of image. Canny's edge detection algorithm is used to find the edges of brain tissue. Region growing is used to partition the brain parts and finally susceptible stroke region is extracted.

J. D. Lee [14] proposed the system for diagnosis of acute stroke utilizing Diffusion Weighted images with Volume Calculation. Firstly, the stroke region is marked and then K-Means clustering and Thresholding algorithm is used to calculate lesion region. Proposed system is compared with traditional method in which benefits of the proposed system like higher accuracy, reduced processing time and 3D reconstruction image is achieved.

**3. SUMMERIZED WORKDONE**

Table I . shows various method of the detection and classification of the stroke which plays vital role in diagnosis of stroke patient

| REF. NO. | METHODOLOGY | | INFERENCE |
|---|---|---|---|
| | PREPROCESSING | DETECTION AND CLASSIFICATION | |
| [4] | Skull stripping by morphological operation, noise removal by median filtering and edge sharpening by un-sharp mask filter. DWT to merge CT and MRI images. | K-Means clustering gives segmentation of stroke region | . Total 16 cases stroke region is identified precisely. Execution time is 12-15s. |
| [5] | Skull part removal using region growing function and noise remove using median filter. Image Enhancement using Laplacian Pyramid | FCM clustering is employed to segment stroke region. | Average processing time of 10.46 s is achieve. |
| [6] | Median filtering is used for the noise removal from MRI images.. GLCM is used for the texture analysis.. | Normal and Abnormal brain classification achieve using Watershed segmentation. Lesion region detected using feature extraction | Efficient method of identifying and detecting lesion from MRI images. Accuracy increased in proposed work |
| [7] | Median filtering for noise removal. Gabor filter is used for texture segmentation. | Seeded region growing is used for identification of infarct and hemorrhage images. | Computational time is very less. MRI is superior than CT images in stroke detection. |
| [8] | Input image analysis is performed with CVB and MTT map. Histogram created for computation of threshold. | Condition of brain tissue is classified. | Result agrees well with expert neurologist manual delineation and produce satisfactory output. |
| [9] | Unwanted part from CT images removed then PDF and CDF calculated. Normalize output used as a transform function applied to input image. | _____ | Proposed method enhanced contrast of soft tissue and achieved EMEE is 3.9409, PSNR is 32.7426 |
| [10] | Five wavelet transforms used for the CT and MRI image fusion. RSME calculated to measure fusion performance. Maximum fusion rule is applied to 3 CT and MRI images. | _____ | Maximum fusion rule achieve smaller RMSE, higher PSNR value and least MSE. |
| [11] | Contrast stretch using windowing operation. Noise is remove using Weiner filter. | Histogram plot is used for the detection of abnormal slices. Daubechies-4 is used for classification. | Average precision obtained is 92% and maximum 93.3% for hemorrhage. The average recall value 90% and maximum 95.915 for acute stroke. |
| [12] | CT image converted to binary, median filtering. Bezier curve to separate hemisphere and feature extracted using co-occurrence matrix. | Classification done using SVM algorithm | Classification accuracy of 98% is achieve. |
| [13] | Anisotropic filter removes noise. Mathematical morphology is used to extract brain images. Median filtering. Edges detected using Canny's algorithm. | . Region Growing is used extract stroke region | Success rate of 85% is achieve is the proposed system |
| [14] | K-Means clustering and | _____ | Higher accuracy, less processing |

| | | | |
|---|---|---|---|
| | Thresholding is used to determine lesion volume | | time and 3D reconstruction image acquired. |

## 4. CONCLUSION

This paper demonstrates a revise on Acute ischemic Stroke Detection and Classification and its development. To diagnose the stroke cases efficient and accurate system is required. Various techniques presented in this paper plays vital role in the detection and classification of stroke. The methods and techniques described in this paper have shown better results in terms of accuracy and processing time. But there is need to improve accuracy and processing time for detection and correct diagnosis of stroke patient.

## REFERENCES

[1] Ray BK, Hazra A, Ghosal M, Banerjee T, Chaudhuri A, Singh V, et al. Early and delayed fatality of stroke in Kolkata, India: Results from a 7-year longitudinal population-based study. J Stroke Cerebrovasc Dis. 2013;22:281–9.

[2] The top 10 causes of death. World Health Organization. http://www.who. int/mediacentre/factsheets/fs310/en/. Accessed March 24, 2015

[3] The internet stroke center. http://www.strokecenter.org/patients/about-stroke/ischemic-stroke/

[4] P. R. Mirajkar, K. A. Bhagwat, ArunVikas Singh, Ashalatha M E."Acute Ischemic Stroke Detection using Wavelet Based Fusion of CT and MRI Images" International Conference on Advances in Computing, Communications and Informatics (ICACCI), 2015

[5] Amina Fatima Zahra Yahiaoui ; Abdelhafid Bessaid. "Segmentation of ischemic stroke area from CT brain images" International Symposium on Signal, Image, Video and Communications (ISIVC) , 2016

[6] Dr. Menaka R , Rohini. S," Efficient Detection of Ischemic Stroke from MRI Images Using Wavelet Transform", International Journal of Computer Science and Information Technology Research Vol. 2, Issue 3, pp: (446-454), Month: July - September 2014

[7] Jeena, R.S.; Kumar, S., "A comparative analysis of MRI and CT brain images for stroke diagnosis", Emerging Research Areas and 2013 International Conference on Microelectronics, Communications and Renewable Energy (AICERA/ICMiCR), 2013 Annual International Conference on , vol., no., pp.1,5, 4-6 June 2013

[8] Md Tabish Raza, S. N. Merchant "A Comparison Based Approach for Brain Tissue Detection under Cerebrovascular Accident (Ischemic) Using CBV and MTT Perfusion Map". IEEE Conference on Information & Communication Technologies,2013.

[9] Tiong-Lang Tan; Kok-Swee Sim; Aun-Kee Chong, "Contrast enhancement of CT brain images for detection of ischemic stroke," Biomedical Engineering (ICoBE), 2012 International Conference on , vol., no., pp.385,388, 27-28 Feb. 2012

[10] K. Parmar, R. K. Kher, F. N. Thakkar "Analysis of CT and MRI Image fusion using Wavelet Transform" International Conference on Communication System and Network Technologies,2012

[11] Chawla, M.; Sharma, S.; Sivaswamy, J.; Kishore, L.T., "A method for automatic detection and classification of stroke from brain CT images," Engineering in Medicine and Biology Society, 2009. EMBC 2009. Annual International Conference of the IEEE , vol., no., pp.3581,3584, 3-6 Sept. 2009

[12] Teena Thomas, Jobin Jose," Computer Aided Detection Of Ischemic Stroke Using Cellular Automata", International Conference On Innovations & Advances In Science, Engineering And Technology [IC -IASET 2014],Volume 3, Special Issue 5, July 2014

[13] Ming Sian Lee; Chiun Li Chin; Ya Wen Lee; Chian Yun Lee; Yan Ru Chen, "Increasing Visual Perception Brain Stroke Detection System," Computing, Measurement, Control and Sensor Network (CMCSN), 2012 International Conference on , vol., no., pp.429,432, 7-9 July 2012

[14] J. D. Lee, T. C. Chang, C. H. Huang, S. J. Wu, C. J. Chen "Computer- aided Diagnosis system for acute stroke using Diffusion Weighted images with Volume Calculation".26th Annual International Conference if the IEEE EMBS,2004.